



PATIENT

Clover Robitaille

PRESENTING CLINICAL SIGNS

History: Grade 4/6 left systolic heart murmur. No current medications.

SPECIES

Canine

BREED

Retriever Mix

SEX

Male Intact

AGE

16 weeks

WEIGHT

25.51lbs

INTERPRETED BY

Maggie Machen Lamy,
DVM, DACVIM
(Cardiology)

IMAGING PERFORMED BY

Kelly Vazquez, CVT

HOSPITAL NAME

Westwood Regional
Veterinary Hospital

REFERRING VET

Dr. Curtis

INVOICE

21678

DATE

10/22/21

ECHOCARDIOGRAM FINDINGS

2D, m-mode, color flow and doppler imaging is available. The left ventricular wall is mildly hypertrophied (0.9cm globally). There is a diffusely hyperechoic endocardium consistent with fibrosis. Mild papillary muscle hypertrophy. The left atrium is normal. The right atrium is normal in size. The right ventricle appears normal. The mitral valve is dysplastic, with an elongated and thickened anterior leaflet that prolapses into the LVOT in systole. There is mild to moderate anterior-directed mitral regurgitation associated with this abnormal motion. No obvious tricuspid regurgitation seen. Blood flow through the LVOT is severely increased. No obvious subaortic ridge is seen. The aortic valve appears mildly thickened. Mild aortic insufficiency. No obvious shunts. No evidence of cardiac tumors or metastatic lesions on this scan. No pleural or pericardial effusion seen.

CARDIAC CHART

CANINE CARDIAC PARAMETERS	MR VMAX (m/s)	TR VMAX (m/s)	LA/AO (Boon method)	LA/AO (Heart Base; Swe)	FS (%)	EF (%)	EPSS (cm)
NORMAL PARAMETER	4.5-5.5	<2.7	1.3	<1.6	28-40	40-100	<0.6
PATIENT	NA	NA	1.3	1.2	30	60	0.19
CANINE CARDIAC PARAMETERS	HR (BPM)	AV VMAX (m/s)	PV MAX (m/s)	BODY WEIGHT (kg)	LA 2D short axis Base view (cm)	LVIDd Avg; 2D and m-mode short axis (cm)	LVIDs Avg; 2D and m-mode short axis (cm)
NORMAL PARAMETER	50-100	0.7-1.7	0.7-1.6	BELOW	BELOW	BELOW	BELOW
PATIENT	104	5.1	0.84	11.6	2.0	2.5	1.2
*Normal chamber parameters expressed as a mean value (SD)				3	1.27 (5.3)	2.46 (2.46)	1.36 (5.5)
BODY WEIGHT DEPENDENT PARAMETERS				5	1.40 (4.5)	2.74 (5.2)	1.60 (4.7)
<i>*Note: All measurements based upon multi-modal images and methods. An average value is reported.</i>				10	1.50 (3.8)	3.27 (3.5)	2.06 (3.1)
				15	1.83 (2.0)	3.71 (2.4)	2.43 (2.1)
				20	2.02 (1.9)	4.14 (2.2)	2.80 (2.0)
				25	2.18 (2.4)	4.48 (2.9)	3.10 (2.5)
				30	2.33 (3.3)	4.83 (3.9)	3.39 (3.4)
				35	2.48 (4.3)	5.17 (5.0)	3.69 (4.5)
				40	2.62 (5.2)	5.48 (6.1)	3.96 (5.4)
				50	2.88 (7.1)	6.07 (8.3)	4.46 (7.4)

Adapted from June Boon, Veterinary Echocardiography, 1998
Rishniw M and Hollis NE, J Vet Intern Med 2000; 14:429-435
Hansson et al, Vet Rad and Ultrasound 2002
Bonagura et al. Echocardiography: principles of interpretation, Vet Clin North Am 15:1177, 1995

INTERPRETATION OF THE FINDINGS & FURTHER RECOMMENDATIONS

The cause of the murmur is increased flow velocity through the LVOT and aortic valve. First, there is mitral valve dysplasia with secondary LVOT obstruction and mitral regurgitation present. This is similar to SAM in a cat, with hypertrophy of the LV secondary to pressure overload caused by obstruction to flow. This type of obstruction tends to be heart rate dependent, with a dynamic profile. Additionally, the aortic valve also appears mildly thickened, likely reflecting a primary valvular issue and mild AI. There is mild LV hypertrophy present indicating pressure overload, however the left atrium is normal indicating the risk for complication is currently low. Mitral stenosis remains a possibility and is not ruled out in this image set. No additional defects are seen; however, it should be mentioned that small defects/shunts are easily missed in congenital echocardiography. Reasonable to recheck once heart rate is controlled and patient is of full



PATIENT

Clover Robitaille

stature (6-12 months) to ensure additional defects are not present. No evidence of volume overload or other secondary changes.

SPECIES

Canine

Lifelong heart rate control with atenolol is recommended, as the dynamic nature of the obstruction will be reduced at lower heart rates. No other medications are indicated at this juncture. Monitor for development of labored breathing, exercise intolerance or collapse episodes, as SAS/AS patients are more predisposed to development of arrhythmias than to CHF. Mild exercise restriction is advised lifelong.

BREED

Retriever Mix

Prognosis is guarded yet highly variable, with many severe AS/SAS patients succumbing by mid-life. My main concern in this case is the young age of the patient as these findings can certainly progress up to 1 year of age. Follow up is highly recommended.

SEX

Male Intact

Once Atenolol is initiated, anesthetic risk is mild. Avoid heart rate stimulating drugs such as atropine or glycopyrrolate unless clinically indicated. Avoid ketamine and acepromazine due to systemic vascular effects. Mild IV fluid restriction is advised. Recommend prophylactic antibiotics for any orthopedic or dental procedure in the future given predisposition to endocarditis.

AGE

16 weeks

PLAN

Administer titrating dose of atenolol: 25mg tablets; Give ¼ tab once daily. Recheck heart rate in 1-2 weeks with target stressed rate of <140bpm, Increase as needed until target reached. Will need to up-titrate to desired effect as puppy grows. Consider referral in any congenital case.

WEIGHT

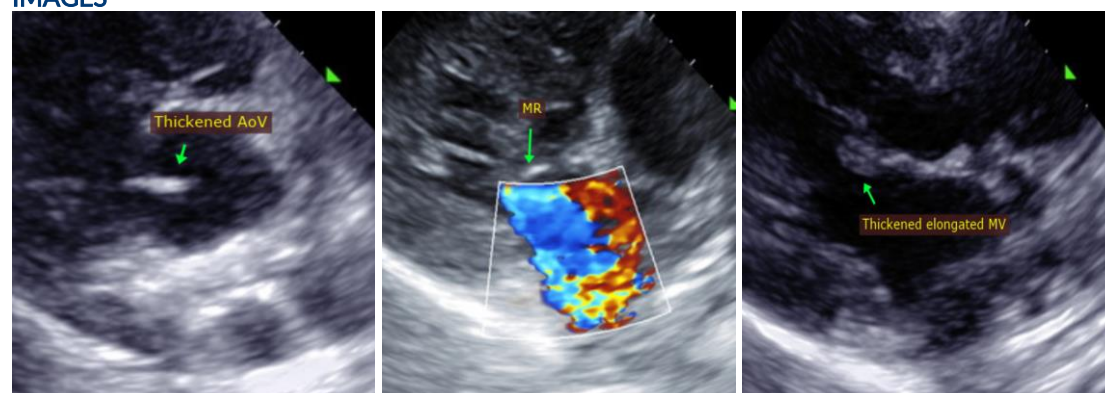
25.51lbs

Recommend recheck echocardiogram in 6-12 months to assess response to atenolol and screen for small concurrent defects, sooner if clinical issues arise.

INTERPRETED BY

Maggie Machen Lamy,
DVM, DACVIM
(Cardiology)

IMAGES



IMAGING

PERFORMED BY

Kelly Vazquez, CVT

The information and recommendations provided are based on the images presented by the referring veterinarian. No evaluation can be communicated regarding pathology that was not visible in the image/video clips provided.

HOSPITAL NAME

Westwood Regional
Veterinary Hospital

REFERRING VET

Dr. Curtis

INVOICE

21678

Thank you for this referral. This report was generated using transcription software, and minor dictation errors may be present. If the clinical or image interpretation does not parallel your findings or if I can be of any further assistance, please contact me.

DATE

10/22/21

Maggie Machen Lamy, DVM
Diplomate of the American College of Veterinary Internal Medicine (Cardiology)
info@sonopath.com